CCB
Cardioangiologisches
Centrum
Bethanien

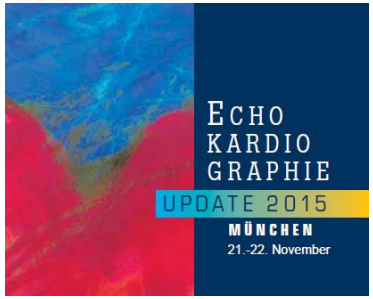

Multimodale Bildgebung bei Aortenerkrankungen

Prof. Dr. Holger Eggebrecht
CCB- Cardioangiologisches Centrum Bethanien
Frankfurt a.M.

Bildgebung bei Aortenerkrankungen

CCB

Tischgeschwindigkeit: 72 cm/s

Scanzeit gesamte Aorta: 1 s

50 ml Kontrastmittel

Aortenerkrankungen: Diagnostik

CCB

European Heart Journal
doi:10.1093/eurheartj/ehu281

ESC GUIDELINES

Bildgebung: CT 1. Wahl

(Gesamte Aorta, nativ + KM)

2014 ESC Guidelines on the diagnosis and treatment of aortic diseases

Document covering acute and chronic aortic diseases of t and abdominal aorta of the adult

The Task Force for the Diagnosis and Treatment of Aort of the European Society of Cardiology (ESC)

Authors/Task Force members: Raimund Erbel* (Chairperson) (Germa Victor Aboyans* (Chairperson) (France), Catherine Boileau (France), Eduardo Bossone (Italy), Roberto Di Bartolomeo (Italy), Holger Eggel (Germany), Arturo Evangelista (Spain), Volkmar Falk (Switzerland), H (Austria), Oliver Gaemperli (Switzerland), Martin Grabenwöger (Aus Axel Haverich (Germany), Bernard Iung (France), Athanasios John Ma Folkert Meijboom (Netherlands), Christoph A. Nienaber (Germany), (Switzerland), Hervé Rousseau (France), Udo Sechtem (Germany), Pe (Norway), Regula S. von Allmen (Switzerland), Christiaan J.M. Vrints (

ESC Committee for Practice Guidelines (CPG): Jose Luis Zamorano (Chairperson) (Spain), Ste (Germany), Helmut Baumgartner (Germany), Jeroen J. Bax (Netherlands), Héctor Bueno (Spai (France), Christi Deaton (UK), Çetin Erol (Turkey), Robert Fagard (Belgium), Roberto Ferrari ((Israel), Arno Hoes (The Netherlands), Paulus Kirchhof (Germany/UK), Juhani Knuuti (Finland)

* Corresponding authors: Raimund Erbel, Department of Cardiology, West-German Heart Centre Essen, University Duisburg-Essen, Hufelandstrass Tel: +49 201 723 4801; Fax: +49 201 723 5401; Email: erbel@uk-essen.de

Victor Aboyans, Department of Cardiology, CHRU Dupuytren Limoges, 2 Avenue Martin Luther King, 87042 Limoges, France. Tel: +33 5 55 05 Email: vaboyans@live.fr

Other ESC entities having participated in the development of this document:

ESC Associations: Acute Cardiovascular Care Association (ACCA), European Association of Cardiovascular Imaging (EACVI), European Association Interventions (EAPCI).

ESC Councils: Council for Cardiology Practice (CCP).

ESC Working Groups: Cardiovascular Magnetic Resonance, Cardiovascular Surgery, Grown-up Congenital Heart Disease, Hypertension and th Cardiac Computed Tomography, Peripheral Circulation, Valvular Heart Disease.

The content of these European Society of Cardiology (ESC) Guidelines has been published for personal and educational use only. No commercial use Guidelines may be translated or reproduced in any form without written permission from the ESC. Permission can be obtained upon submission of a writ Press, the publisher of the European Heart Journal and the party authorized to handle such permissions on behalf of the ESC.

Disclaimer: The ESC Guidelines represent the views of the ESC and were produced after careful consideration of the scientific and medical knowledge and the evidence available at the time of their dating.

The ESC is not responsible in the event of any contradiction, discrepancy and/or ambiguity between the ESC Guidelines and any other official recommendations or guidelines issued by the relevant public health authorities, in particular in relation to good use of health care or therapeutic strategies. Health professionals are encouraged to take the ESC Guidelines fully into account when exercising their clinical judgment, as well as in the determination and the implementation of preventive, diagnostic or therapeutic medical strategies; however, the ESC Guidelines do not override, in any way whatsoever, the individual responsibility of health professionals to make appropriate and accurate decisions in consideration of each patient's health condition and in consultation with that patient and, where appropriate and/or necessary, the patient's caregiver. Nor do the ESC Guidelines exempt health professionals from taking full and careful consideration of the relevant official updated recommendations or guidelines issued by the competent public health authorities in order to manage each patient's case in light of the scientifically accepted data pursuant to their respective ethical and professional obligations. It is also the health professional's responsibility to verify the applicable rules and regulations relating to drugs and medical devices at the time of prescription.

National Cardiac Societies document reviewers: listed in the Appendix.

© The European Society of Cardiology 2014. All rights reserved. For permissions please email: journals.permissions@oup.com.

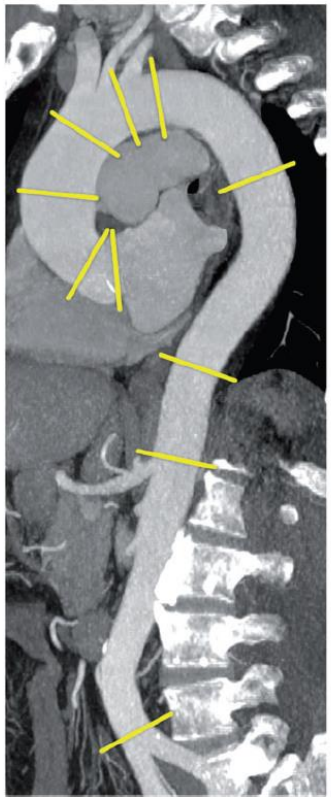

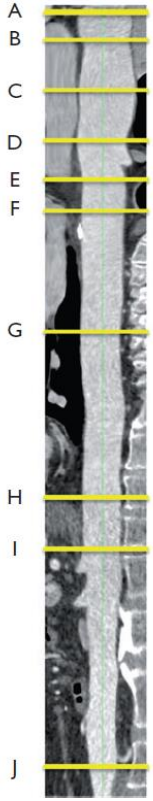

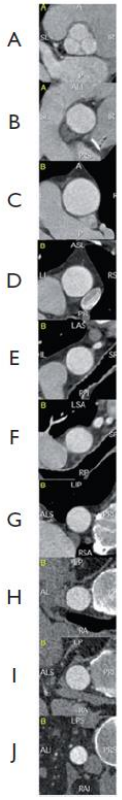

Durchmesserbestimmung:

- perpendikular
- Definierte „landmarks“
- **> 3mm Zunahme = relevant**

European Heart Journal
doi:10.1093/eurheartj/ehu281

CCB

2014 ESC Guidelines on the diagnosis and treatment of aortic diseases

Document covering acute and chronic aortic diseases of the thoracic and abdominal aorta of the adult

The Task Force for the Diagnosis and Treatment of Aortic Diseases of the European Society of Cardiology (ESC)

Authors/Task Force members: Raimund Erbel* (Chairperson) (Germany), Victor Aboyans* (Chairperson) (France), Catherine Boileau (France), Eduardo Bossone (Italy), Roberto Di Bartolomeo (Italy), Holger Eggebrecht (Germany), Arturo Evangelista (Spain), Volkmar Falk (Switzerland), Herbert Frank (Austria), Oliver Gaemperli (Switzerland), Martin Grabenwöger (Austria),

	Sensitivität	Spezifität	Positiver prädiktiver Wert	Negativer prädiktiver Wert
TEE	99%	89%	89%	99%
CT-A	98%	96%	---	---
MR-A	98%	98%	---	---

ESC Working Groups: Cardiovascular Magnetic Resonance, Cardiovascular Surgery, Grown-up Congenital Heart Disease, Hypertension and the Heart, Nuclear Cardiology and Cardiac Computed Tomography, Peripheral Circulation, Valvular Heart Disease.

The content of these European Society of Cardiology (ESC) Guidelines has been published for personal and educational use only. No commercial use is authorized. No part of the ESC Guidelines may be translated or reproduced in any form without written permission from the ESC. Permission can be obtained upon submission of a written request to Oxford University Press, the publisher of the European Heart Journal and the party authorized to handle such permissions on behalf of the ESC.

Disclaimer: The ESC Guidelines represent the views of the ESC and were produced after careful consideration of the scientific and medical knowledge and the evidence available at the time of their dating.

The ESC is not responsible in the event of any contradiction, discrepancy and/or ambiguity between the ESC Guidelines and any other official recommendations or guidelines issued by the relevant public health authorities, in particular in relation to good use of health care or therapeutic strategies. Health professionals are encouraged to take the ESC Guidelines fully into account when exercising their clinical judgment, as well as in the determination and the implementation of preventive, diagnostic or therapeutic medical strategies; however, the ESC Guidelines do not override, in any way whatsoever, the individual responsibility of health professionals to make appropriate and accurate decisions in consideration of each patient's health condition and in consultation with that patient and, where appropriate and/or necessary, the patient's caregiver. Nor do the ESC Guidelines exempt health professionals from taking full and careful consideration of the relevant official updated recommendations or guidelines issued by the competent public health authorities in order to manage each patient's case in light of the scientifically accepted data pursuant to their respective ethical and professional obligations. It is also the health professional's responsibility to verify the applicable rules and regulations relating to drugs and medical devices at the time of prescription.

National Cardiac Societies document reviewers: listed in the Appendix.

© The European Society of Cardiology 2014. All rights reserved. For permissions please email: journals.permissions@oup.com.

European Heart Journal
doi:10.1093/eurheartj/ehu281

CCB

2014 ESC Guidelines on the diagnosis and treatment of aortic diseases

Document covering acute and chronic aortic diseases of the thoracic and abdominal aorta of the adult

The Task Force for the Diagnosis and Treatment of Aortic Diseases of the European Society of Cardiology (ESC)

Table 3 Comparison of methods for imaging the aorta

Advantages/disadvantages	TTE	TOE	CT	MRI	Aortography
Ease of use	+++	++	+++	++	+
Diagnostic reliability	+	+++	+++	+++	++
Bedside/interventional use[a]	++	++	–	–	++
Serial examinations	++	+	++(+)[b]	+++	–
Aortic wall visualization[c]	+	+++	+++	+++	–
Cost	–	–	– –	– – –	– – –
Radiation	0	0	– – –	–	– –
Nephrotoxicity	0	0	– – –	– –	– – –

+ means a positive remark and—means a negative remark. The number of signs indicates the estimated potential value

[a]IVUS can be used to guide interventions (see web addenda)

[b]+++ only for follow-up after aortic stenting (metallic struts), otherwise limit radiation

[c]PET can be used to visualize suspected aortic inflammatory disease

CT = computed tomography; MRI = magnetic resonance imaging; TOE = transoesophageal echocardiography; TTE = transthoracic echocardiography.

time of their dating.

The ESC is not responsible in the event of any contradiction, discrepancy and/or ambiguity between the ESC Guidelines and any other official recommendations or guidelines issued by the relevant public health authorities, in particular in relation to good use of health care or therapeutic strategies. Health professionals are encouraged to take the ESC Guidelines fully into account when exercising their clinical judgment, as well as in the determination and the implementation of preventive, diagnostic or therapeutic medical strategies; however, the ESC Guidelines do not override, in any way whatsoever, the individual responsibility of health professionals to make appropriate and accurate decisions in consideration of each patient's health condition and in consultation with that patient and, where appropriate and/or necessary, the patient's caregiver. Nor do the ESC Guidelines exempt health professionals from taking full and careful consideration of the relevant official updated recommendations or guidelines issued by the competent public health authorities in order to manage each patient's case in light of the scientifically accepted data pursuant to their respective ethical and professional obligations. It is also the health professional's responsibility to verify the applicable rules and regulations relating to drugs and medical devices at the time of prescription.

National Cardiac Societies document reviewers: listed in the Appendix.

© The European Society of Cardiology 2014. All rights reserved. For permissions please email: journals.permissions@oup.com.

TEE: Darstellung der Aorta

CCB

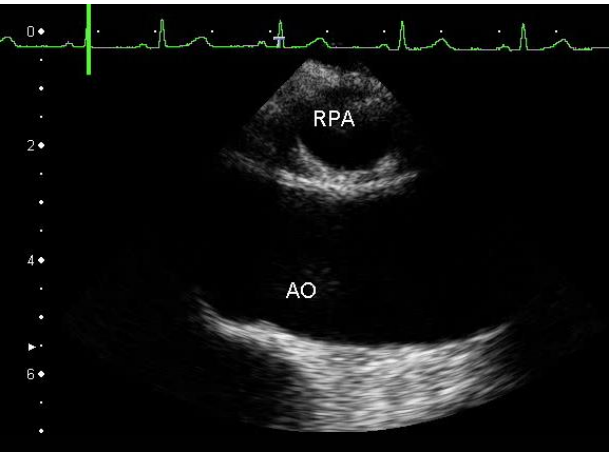

Midesophageal Ao asc LAX
(„Banana“-View, 120°)

Midesophageal AV LAX (120°)

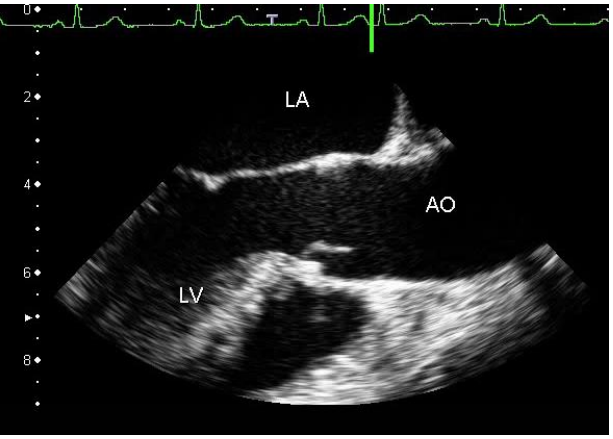

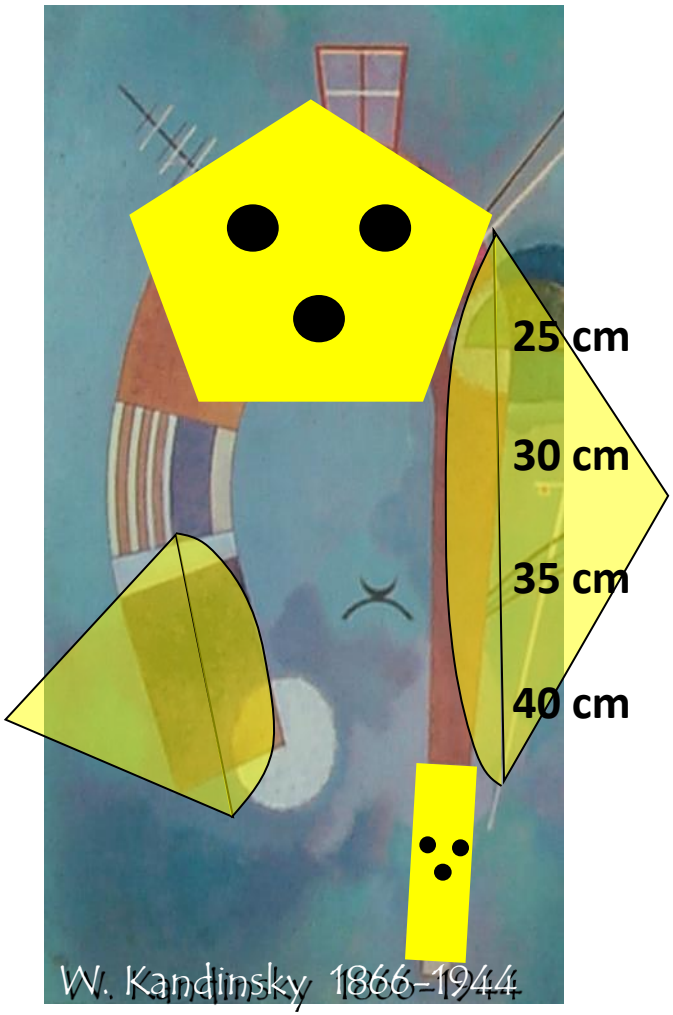

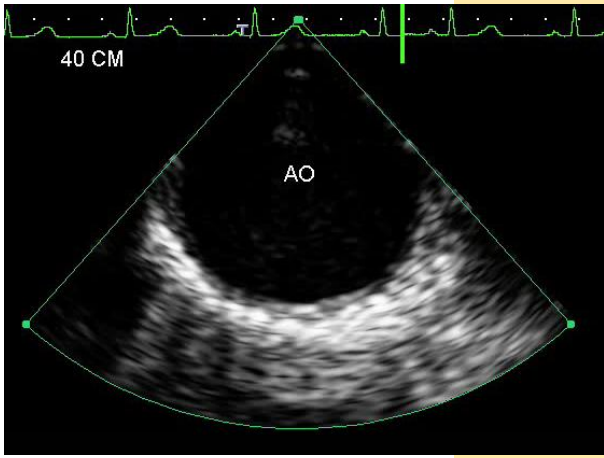

Desc aortic SAX (0°)

Desc aortic LAX (90°)

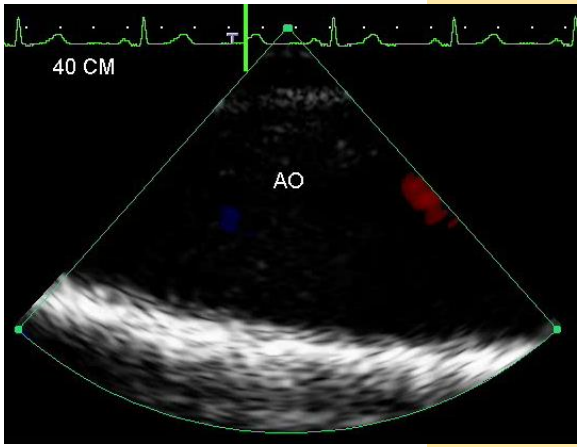

Artefakte

CCB

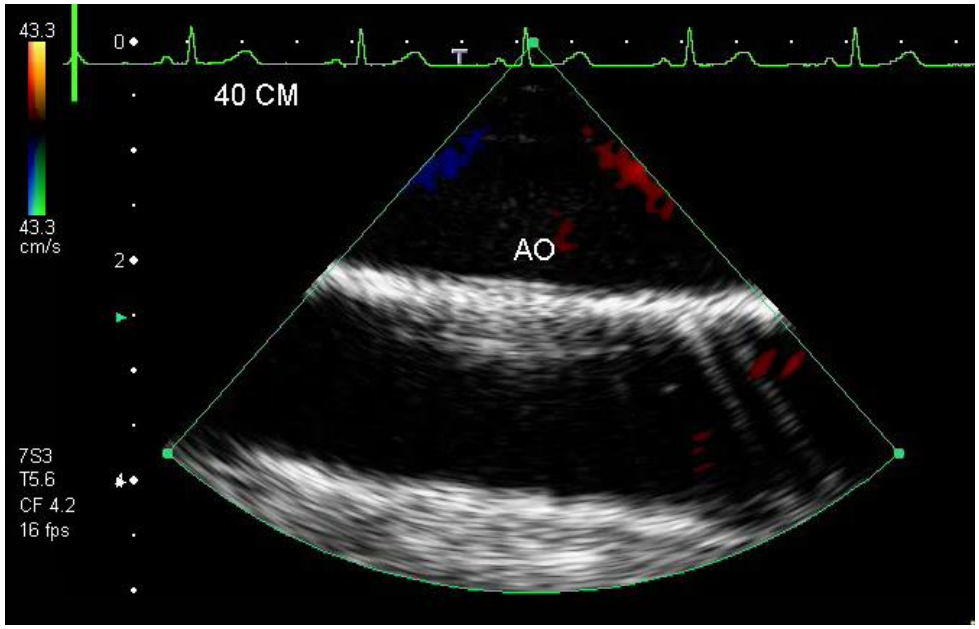

TEE: Reverberationsartefakt

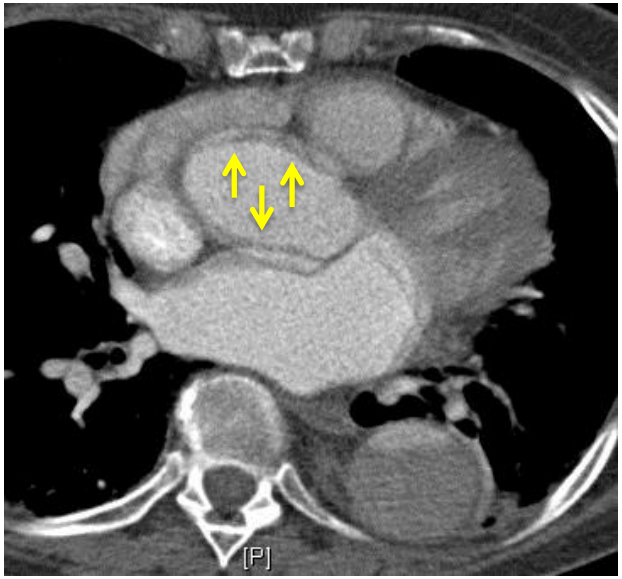

CT: Ascendens ohne EKG-Triggerung

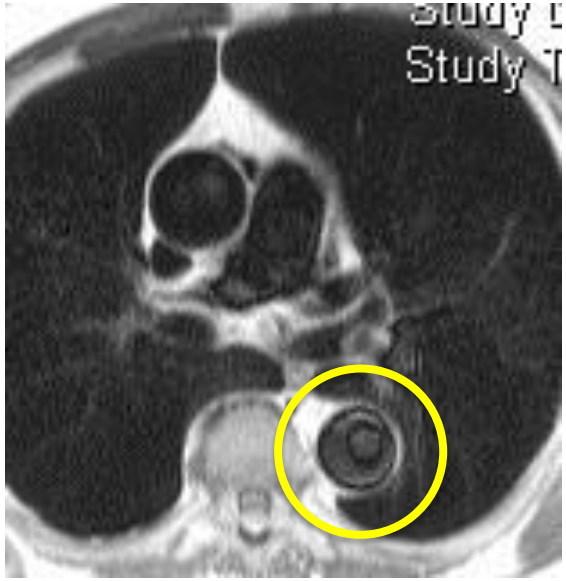

MRT: slow flow bei HASTE

Aortendissektion

De Bakey	Type I	Type II	Type III
Stanford	Type A	Type A	Type B

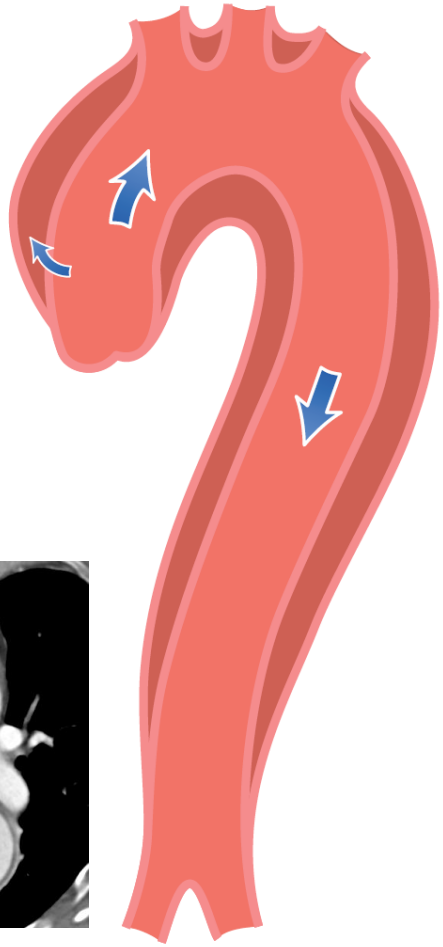

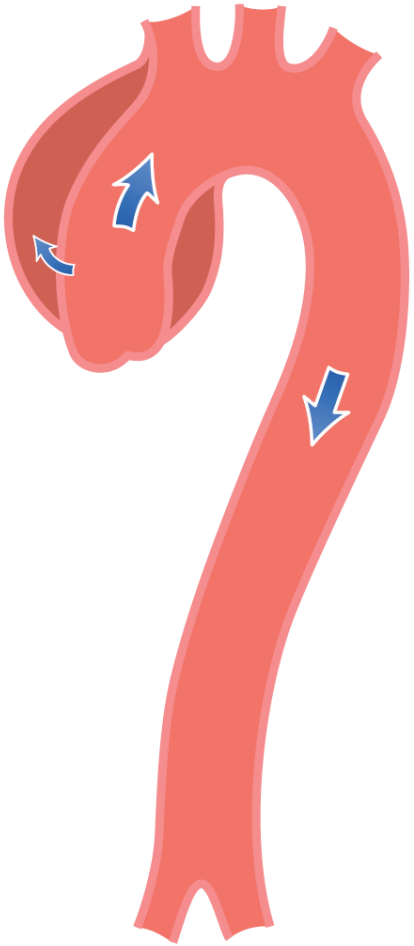

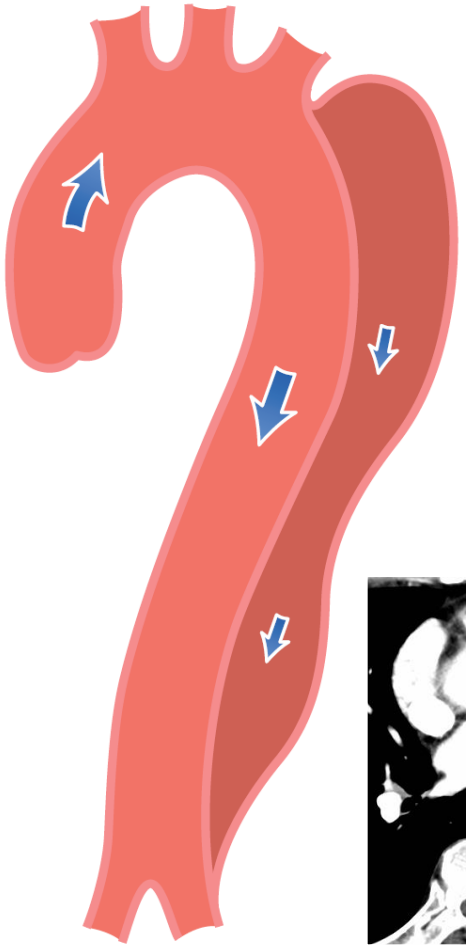

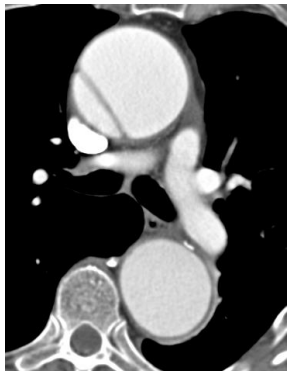

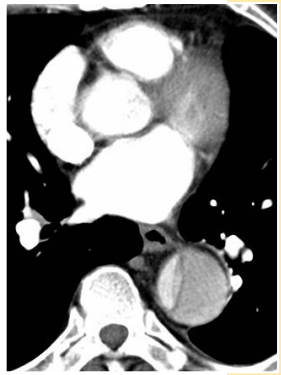

Bildgebung bei Aortendissektion

CCB

Ziele der Bildgebung	TEE	CT
Darstellung **Dissektionslamelle**	+++	+++
Ausdehnung der Dissektion	+ (Ascendens, Descendens thorakal)	+++
Lokalisation **Entry** / Re-Entry	++	++
Antegrade / Retrograde Dissektion	++	+++
Beurteilung **Aortenklappeninsuffizienz**	**+++**	**-**
Seitastbeteiligung	-	+++
Berurteilung **Malperfusion**	++ (dynamische Kompression)	++ (statisch)
Detektion **Organischämie** (Hirn, Moykard, Darm, Niere)	-	+++
Beurteilung **Perikarderguss**	+++	++
Beurteilung Pleuraerguss	++	+++
Detektion Periaortale Blutung	+	+++
Mediastinale Blutung	+	+++
Zusätzlich bestehende Aortenpathologie (Aneurysma, Plaques, Zeichen der Inflammation)	++	+++

Erbel R ESC Guideline 2014

Bildgebung bei Aortendissektion

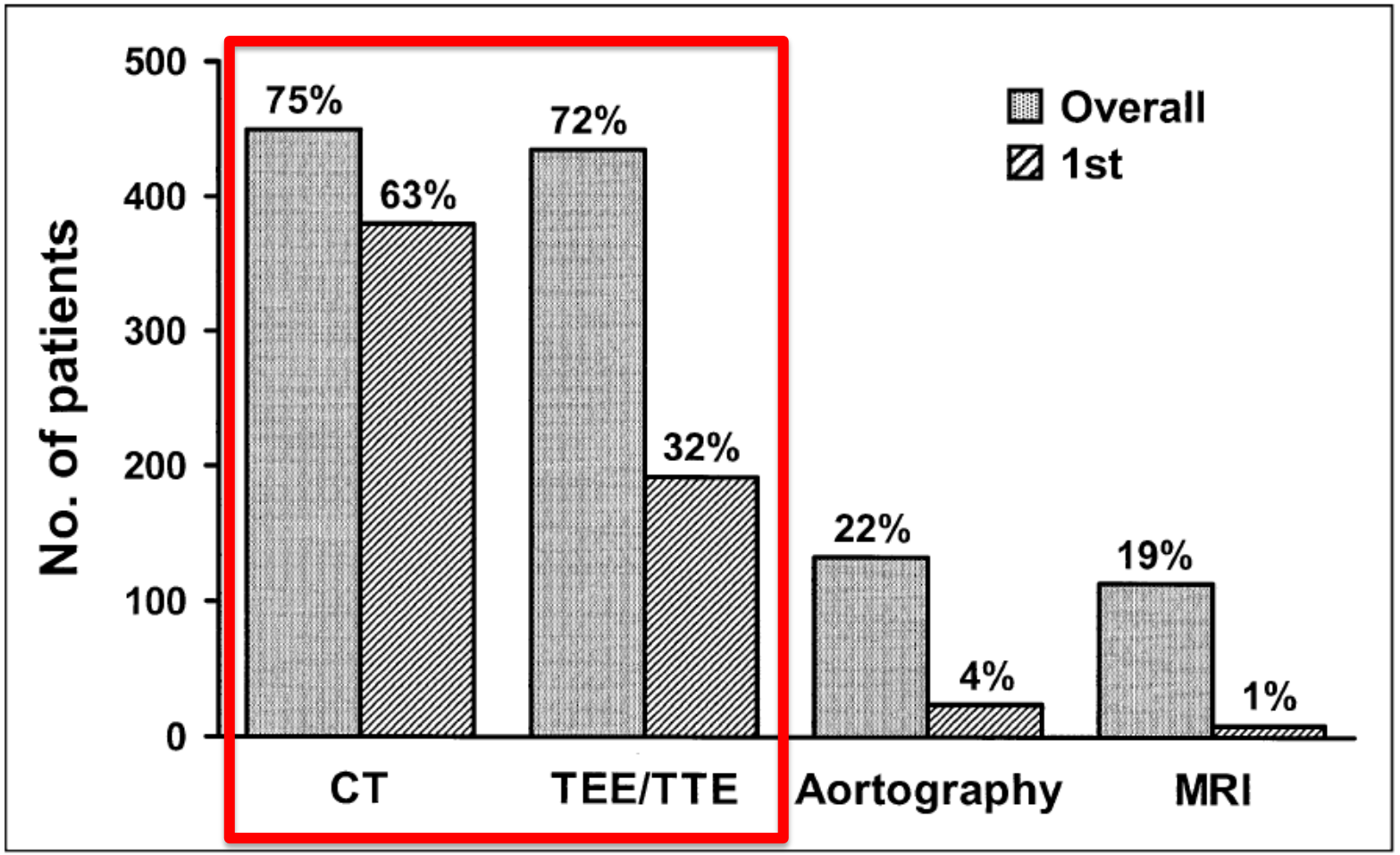

FIGURE 1. Overall number and percentage of study patients according to imaging study and the number and percentage according to imaging study of first choice. TTE = transthoracic echocardiography.

Moore AG Am J Cardiol 2002

Akutes Aortensyndrom im TTE

CCB

42 J, ♂, akute Brustschmerzen, bek. Marfan Syndrom

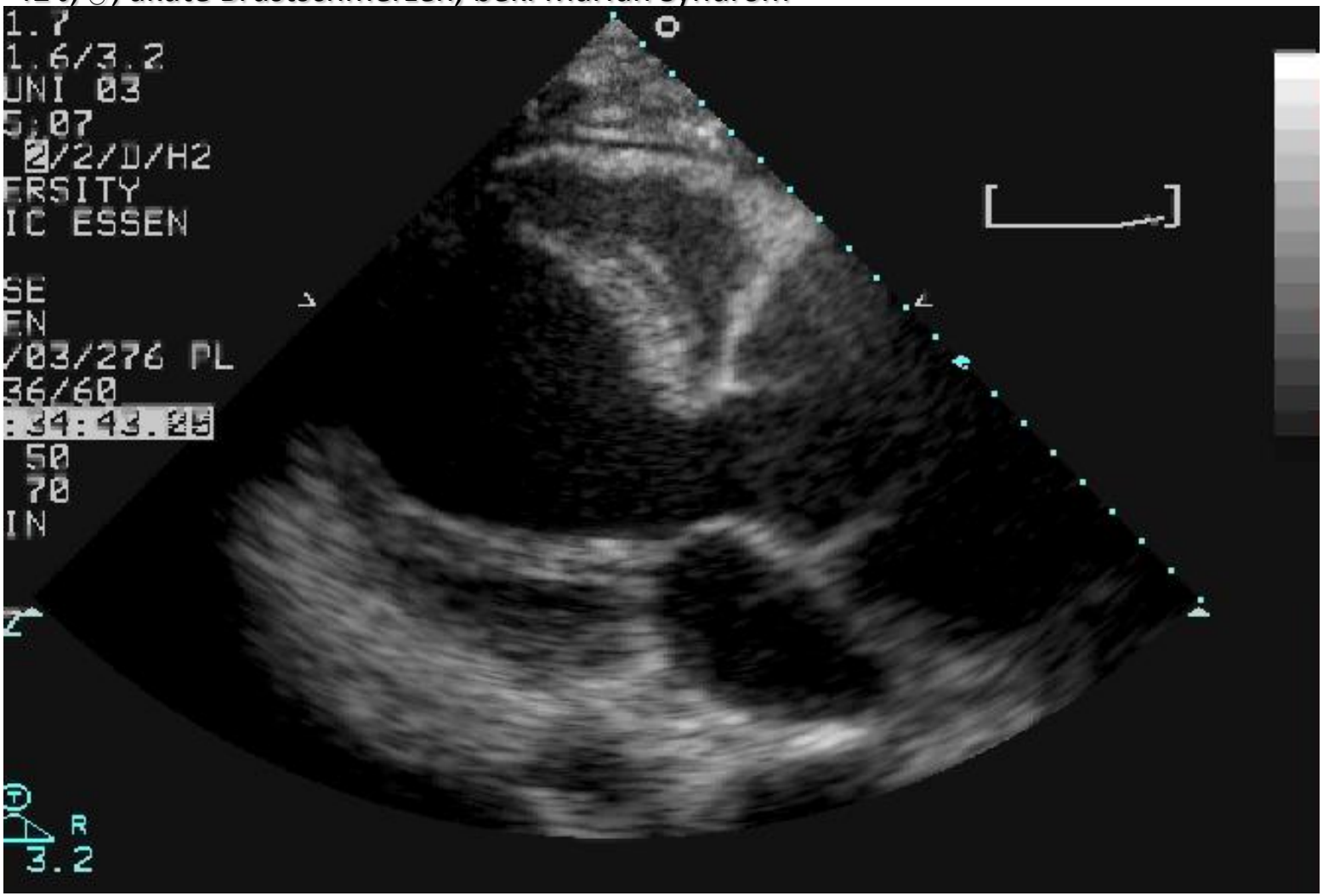

Wichtige Zusatzinfo: Pericarderguss !

TEE: Darstellung der Dissektionslamelle

CCB

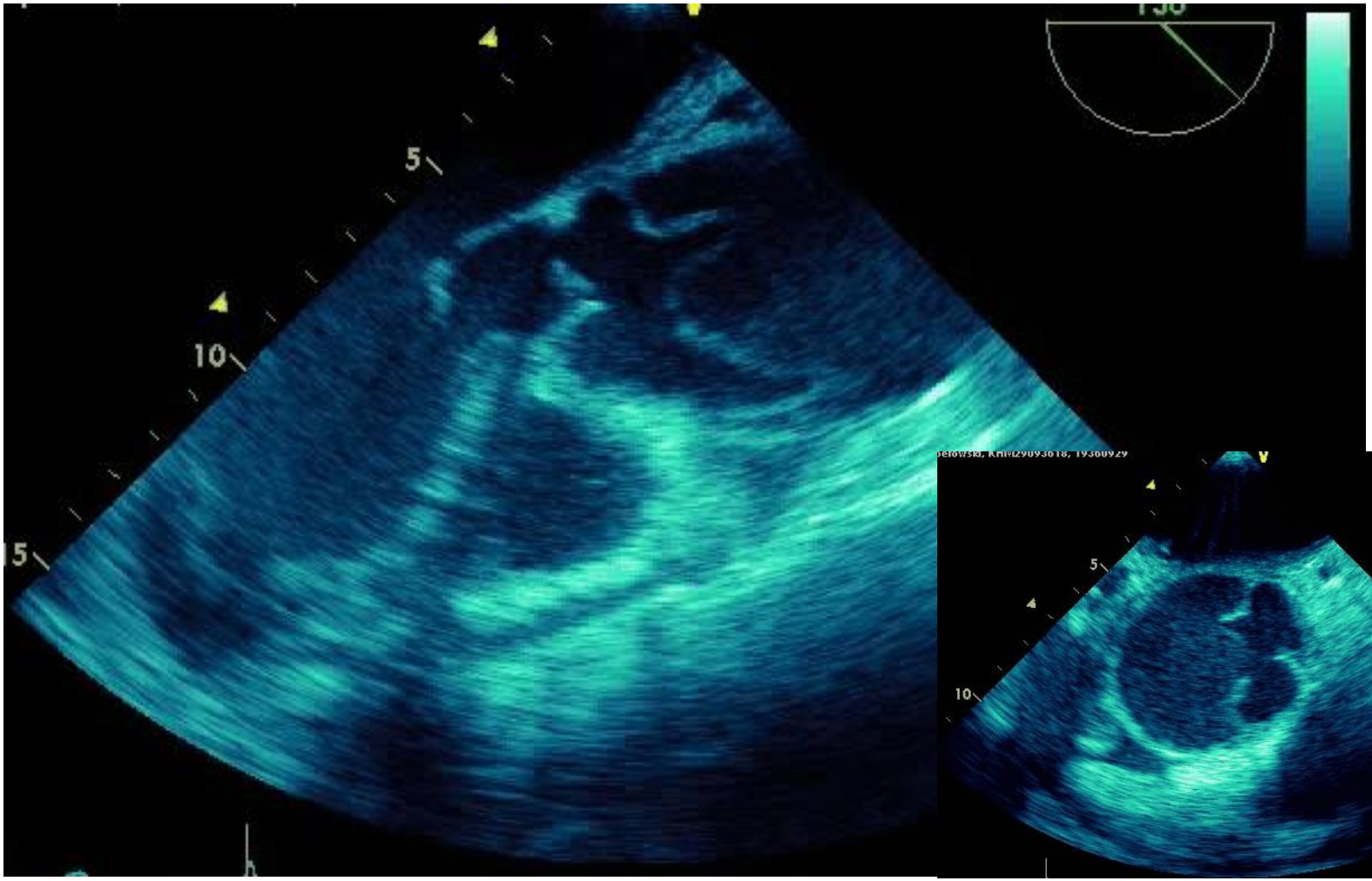

LAX

SAX

TEE: Darstellung der Dissektionslamelle

Ausdehnung der Dissektion: Descendens

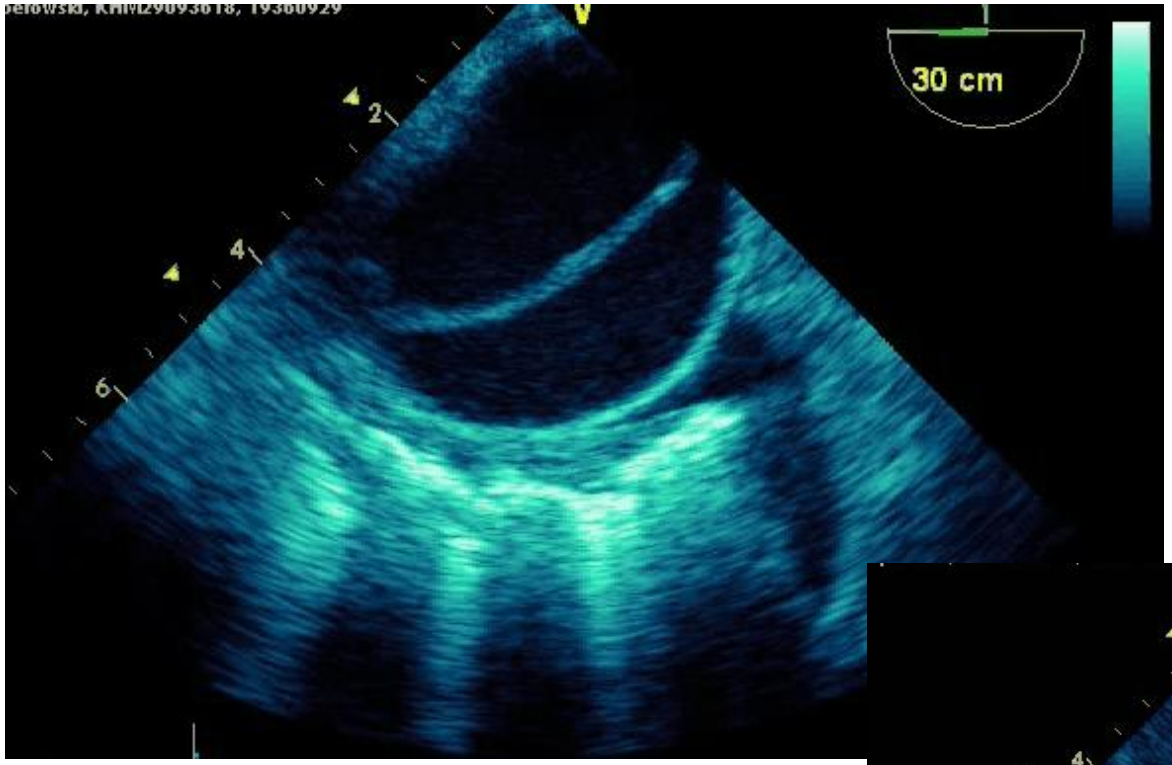

Desc aortic SAX, 30 cm

Desc aortic SAX, 38 cm

Wichtige Zusatzinfo: Pleuraerguss !

Entry / Re-entry Beurteilung

CCB

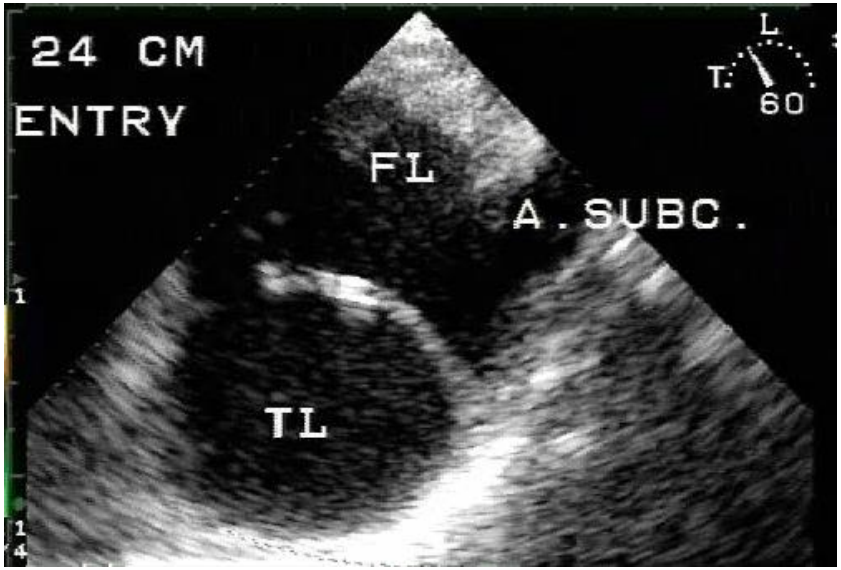

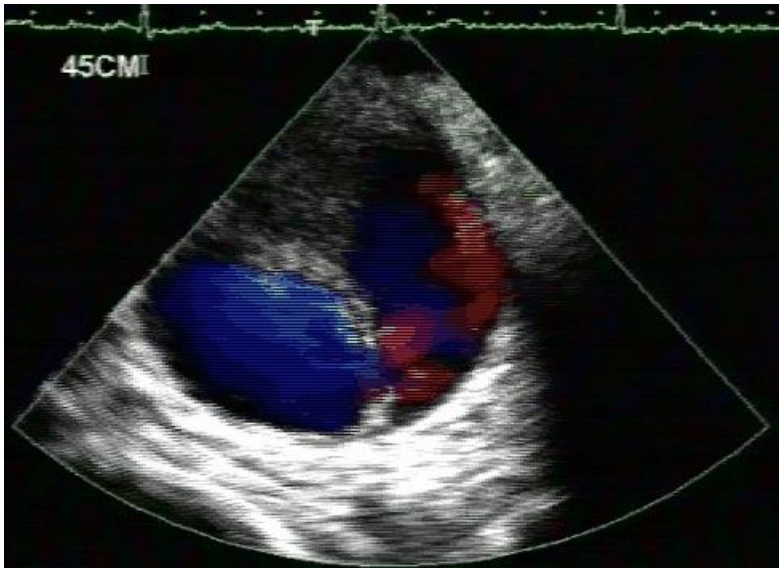

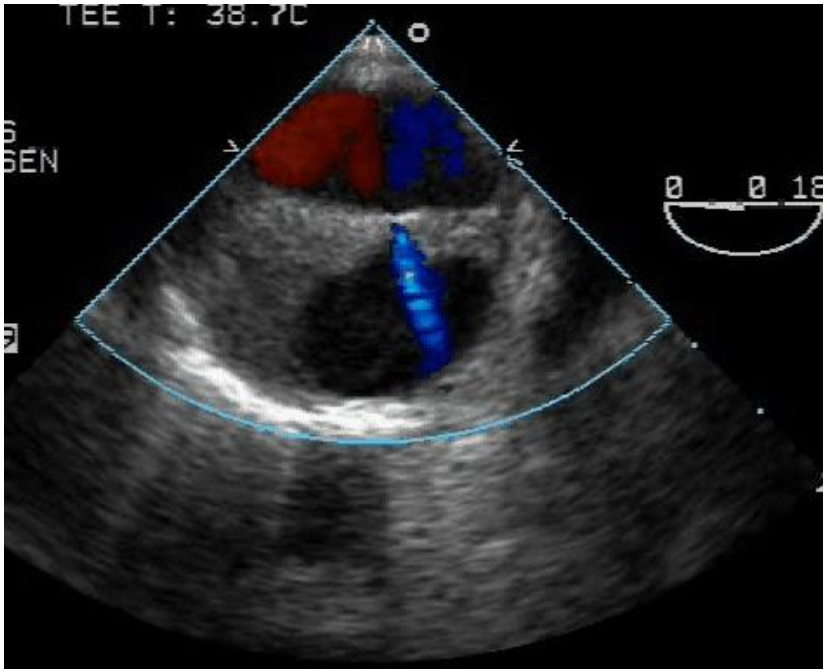

TEE: Dynamische Malperfusion durch Kompression des wahren Lumens

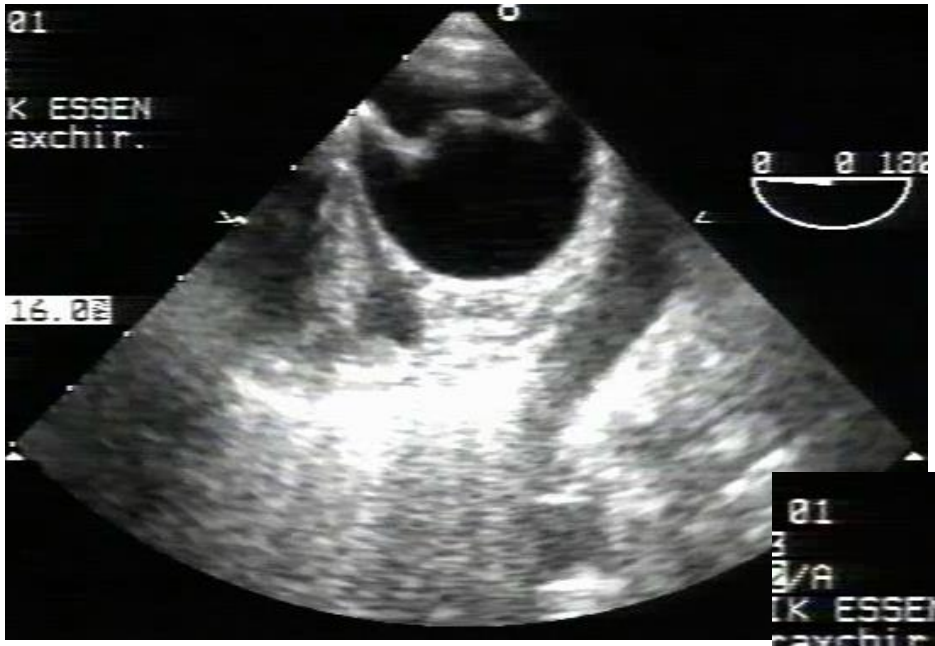

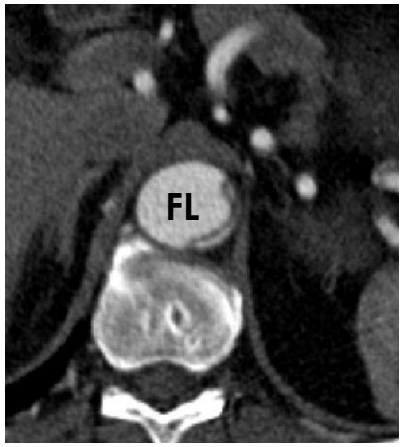

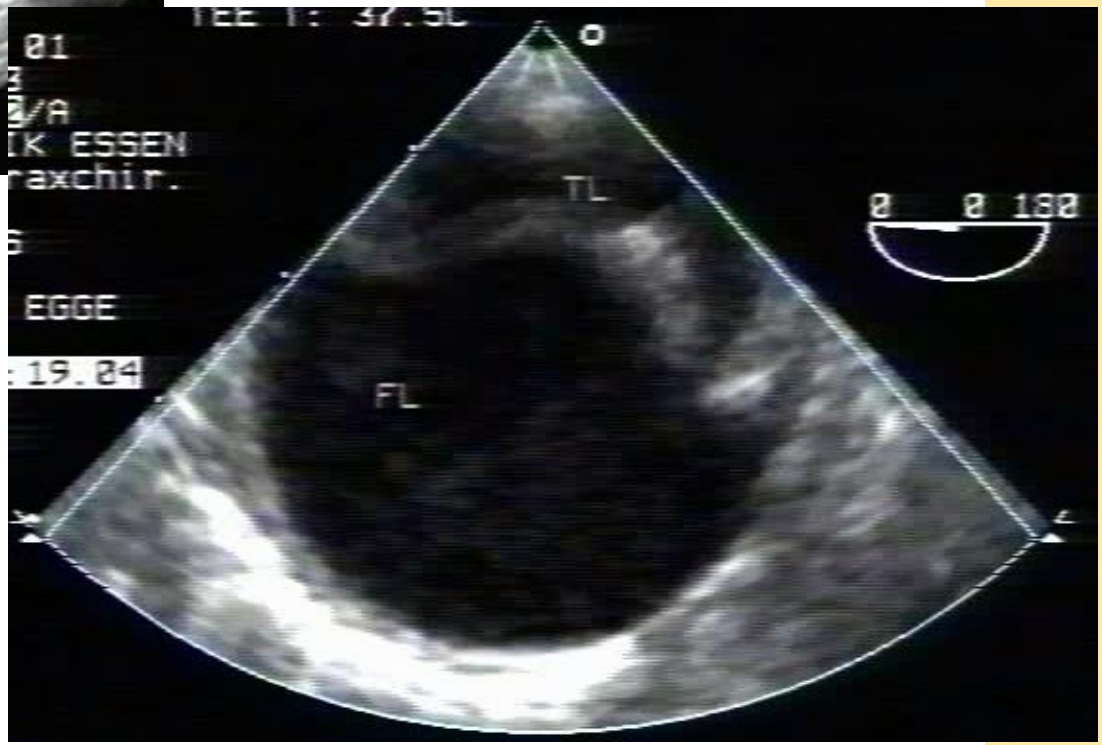

CT: Malperfusion durch statische Einbeziehung von Organarterien

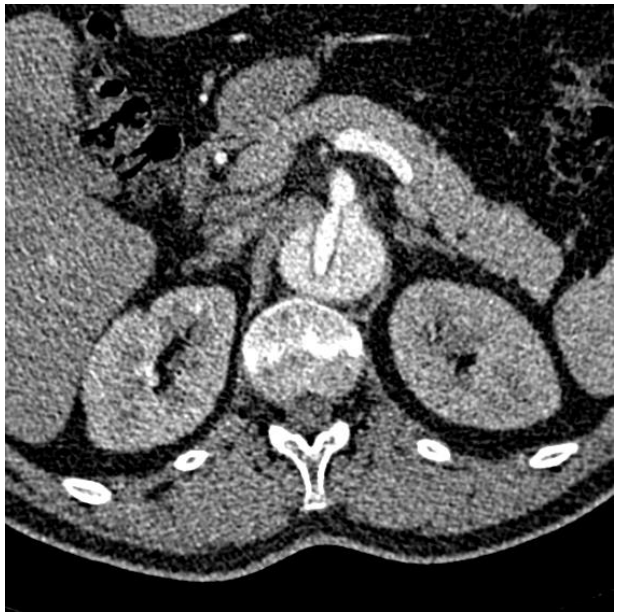

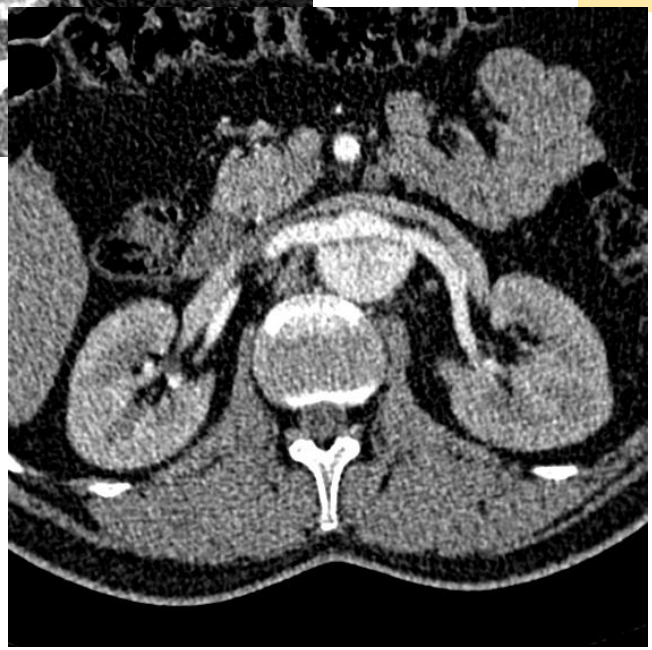

Beurteilung Aorteninsuffizienz

CCB

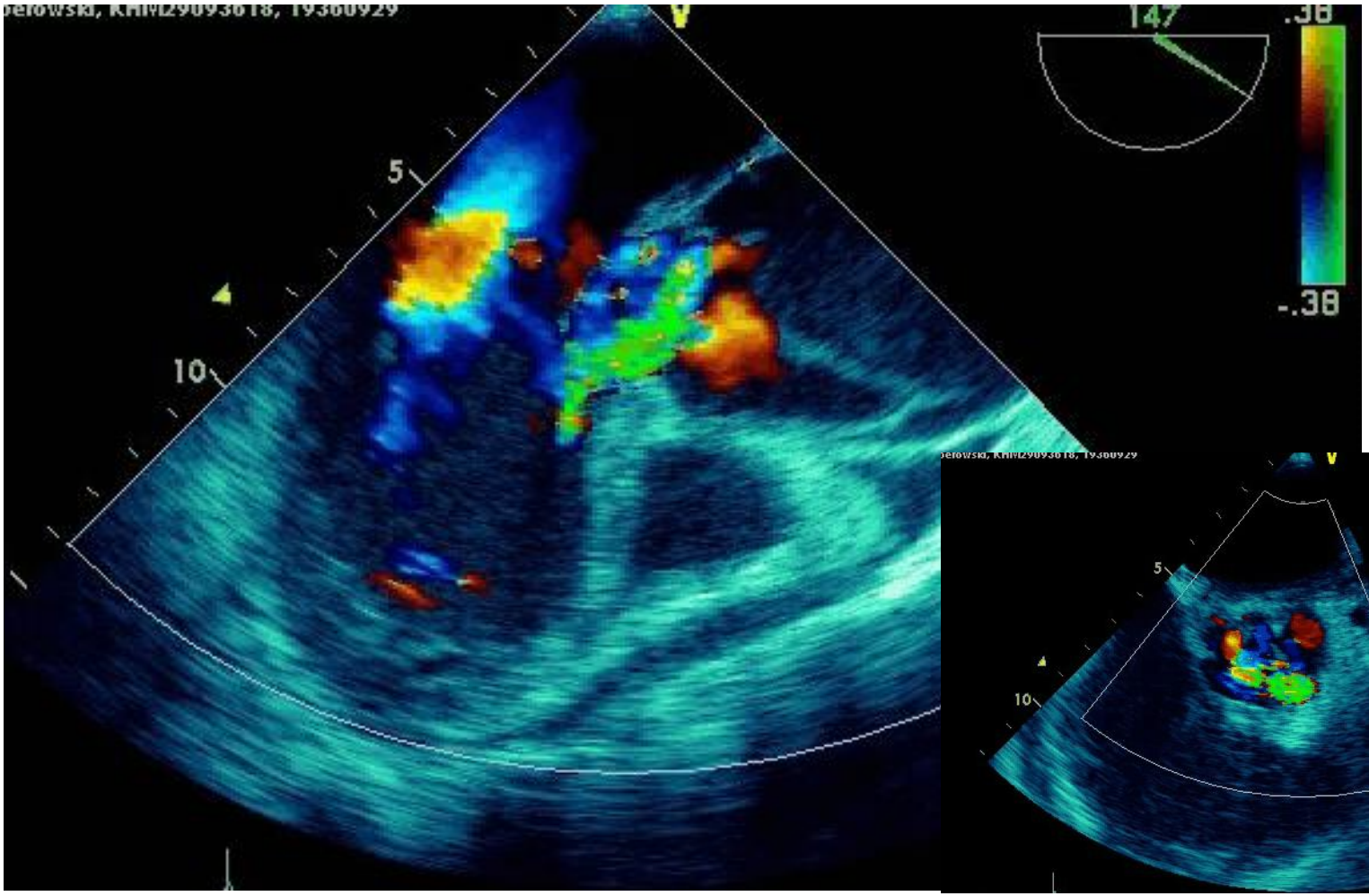

LAX

SAX

MRA: Aortendissektion

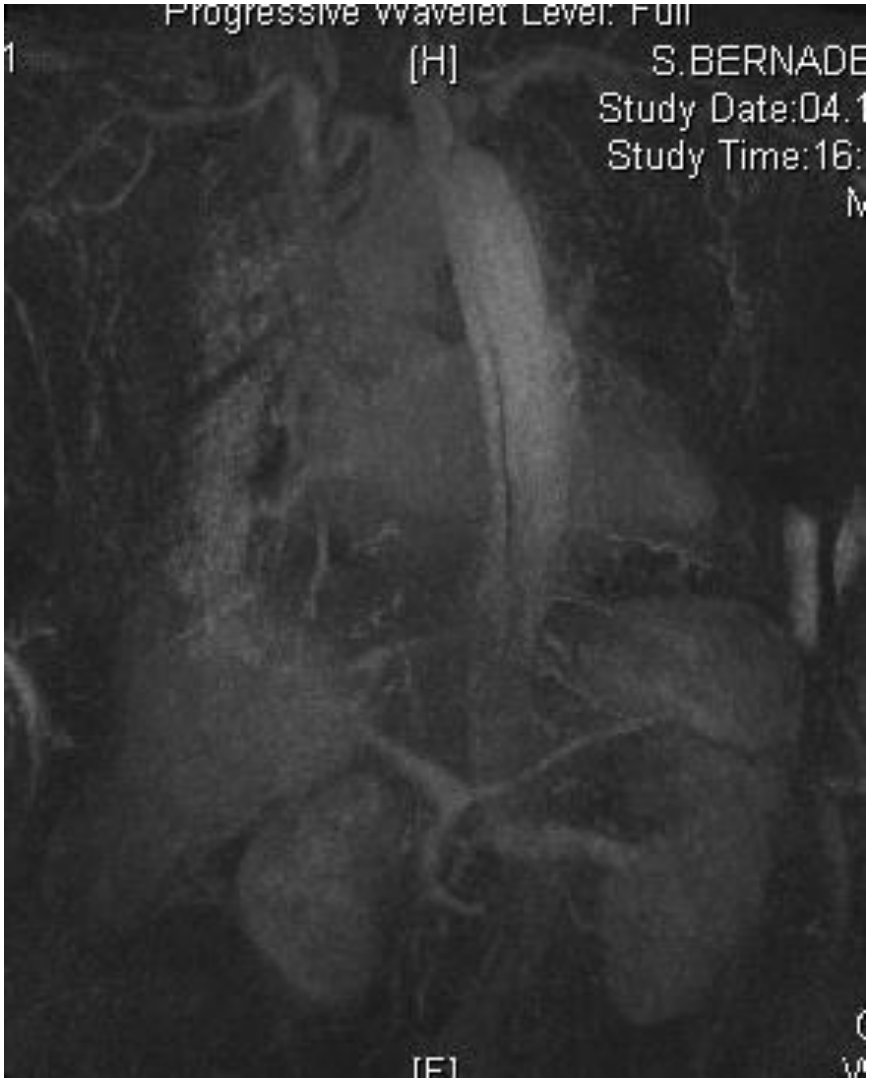

4D Twist MRA: Dynamische Flussbeurteilung

Hybridbildgebung: PET-CT / PET-MRT

CCB

Detection of inflammation in patients with acute aortic syndrome: comparison of FDG-PET/CT imaging and serological markers of inflammation

H Kuehl,[1] H Eggebrecht,[2] T Boes,[3] G Antoch,[1] S Rosenbaum,[4] S Ladd,[1] A Bockisch,[4] J Barkhausen,[1] R Erbel[2]

[1] Department for Diagnostic and Interventional Radiology and Neuroradiology, Essen, Germany; [2] Department of Cardiology, West German Heart Center, Essen, Germany; [3] Institute for Medical

ABSTRACT

Objective: A substantial number of patients with acute aortic syndrome (AAS) require invasive therapy because of disease progression. Our study aimed to assess the impact of positron emission tomography (PET)/computed tomography (CT) and serological markers of inflammation

FDG-PET alone is limited by the low spatial resolution and a lack of morphological information. This can be overcome with the dual-modality PET/computed tomography (CT), which has emerged as a new diagnostic technique for vascular applications. Among those, acute aortic syndrome (AAS) belongs

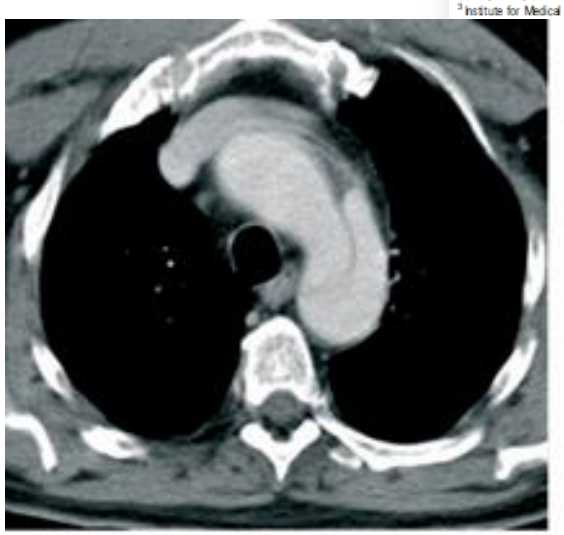

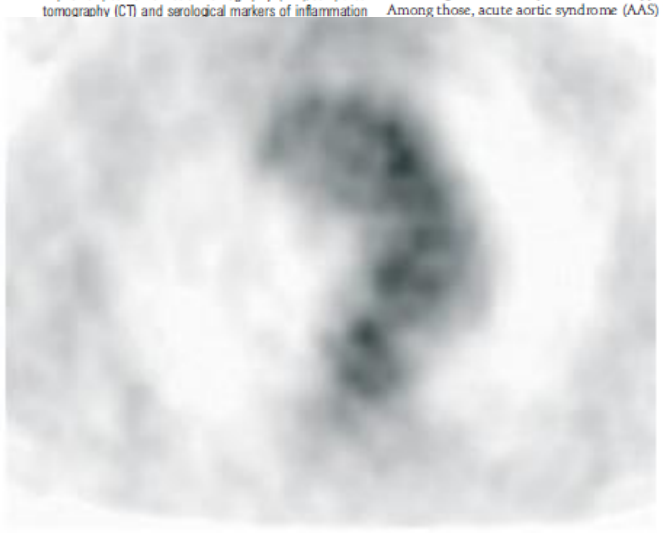

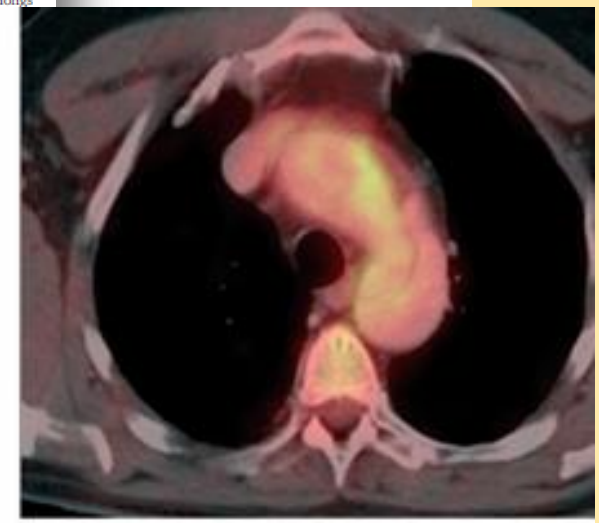

CT

PET

PET-CT

(FDG)-positron emission tomo... shown excellent results in the d... diseases, based on the detection ... metabolism. In oncology there ... indications for FDG-PET, inclu... malignant tumours, tumour staging and therapy control.[1] In patients with inflammatory vascular diseases FDG-PET can be helpful for monitoring therapy response.[2-4] For atherosclerotic abdominal aortic aneurysms, a strong correlation was found between increased FDG-PET uptake and the progression of aneurysm size.[5] Furthermore, there is a correlation between the stage of plaque development and the level of glucose metabolism within atherosclerotic plaques.[6] Advanced plaques are more likely to show increased tracer uptake, as a result of the accumulation of active macrophages.[7]

...dality PET/CT was performed using the ... system (Siemens Medical Solutions, ... Estates, IL, USA). The system acquires ...rst, followed by PET.[8] ...ages were acquired with 130 mA, 130 kV, ...idth of 5 mm and table feed of 8 mm per rotation. Whole-body spiral CT was performed starting at the upper thigh and scanning in the caudocranial direction up to the neck. This CT scan was used for the attenuation correction of the PET data. It was performed without intravenous contrast to avoid hardening artefacts and to identify hyperdense intramural haematomas. A limited breath-hold technique was used to avoid motion-induced artefacts.[14]

Patients had been instructed to fast for a minimum of 6 hours before tracer injection. In addition, blood samples were collected immediately before the

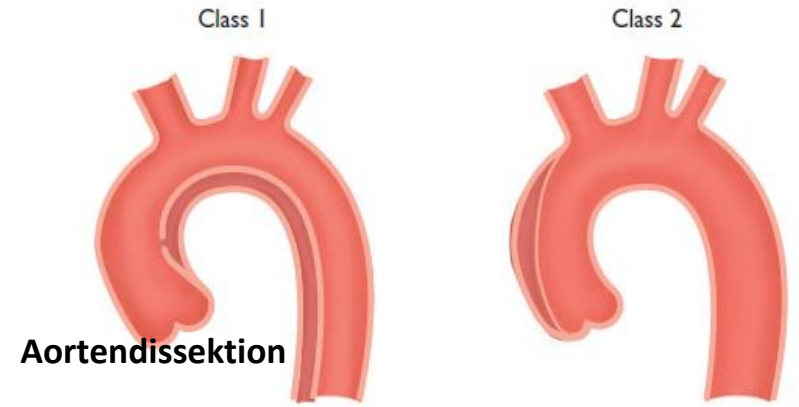

Aortendissektion

IMH-Intramurales Hämatom

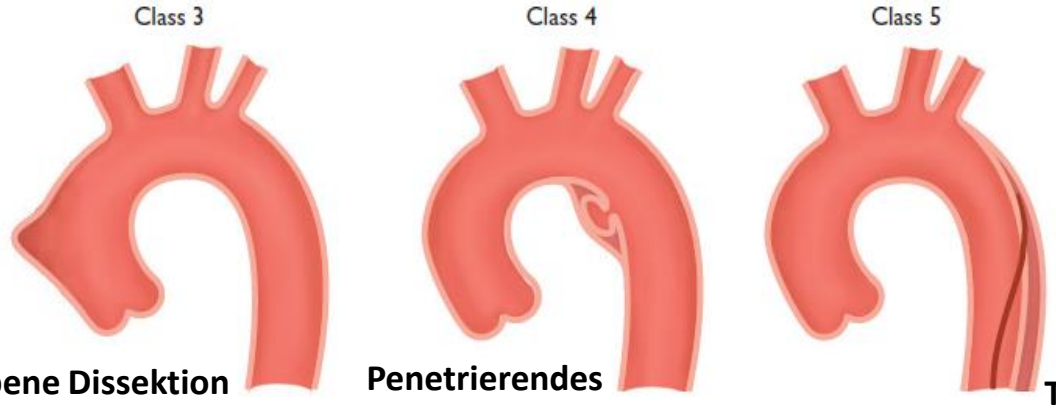

Umschriebene Dissektion

Penetrierendes Aortenulcus-PAU

Traumatische/ Iatrogene Dissektion

Figure 5 Classification of acute aortic syndrome in aortic dissection.[1,141]

Class 1: Classic AD with true and FL with or without communication between the two lumina.
Class 2: Intramural haematoma.
Class 3: Subtle or discrete AD with bulging of the aortic wall.
Class 4: Ulceration of aortic plaque following plaque rupture.
Class 5: Iatrogenic or traumatic AD, illustrated by a catheterinduced separation of the intima.

Bildgebung bei IMH / PAU

CCB

IMH

Aufgabe der Bildgebung	TEE	CT
Lokalisation und **Ausdehnung** der Wandverdickung (IMH)	+ (Ascendens, Descendens thorakal)	+++
Zusätzliche bestehende Atherosklerose (intimaler Kalkverschiebung)	+	+++
Darstellung kleinerer **intimaler Einrisse**	++	++

PAU

Aufgabe der Bildgebung	TEE	CT
Lokalisation des PAU (Länge/Tiefe)	+ (Ascendens, Descendens thorakal)	+++
Zusätzlich bestehendes **IMH**	++	+++
Beteiligung des peri-aortalen Gewebes und Blutung	+	+++
Dicke der verbleibenden Aortenwand	++	++

TEE: Intramurales Hämatom (IMH)

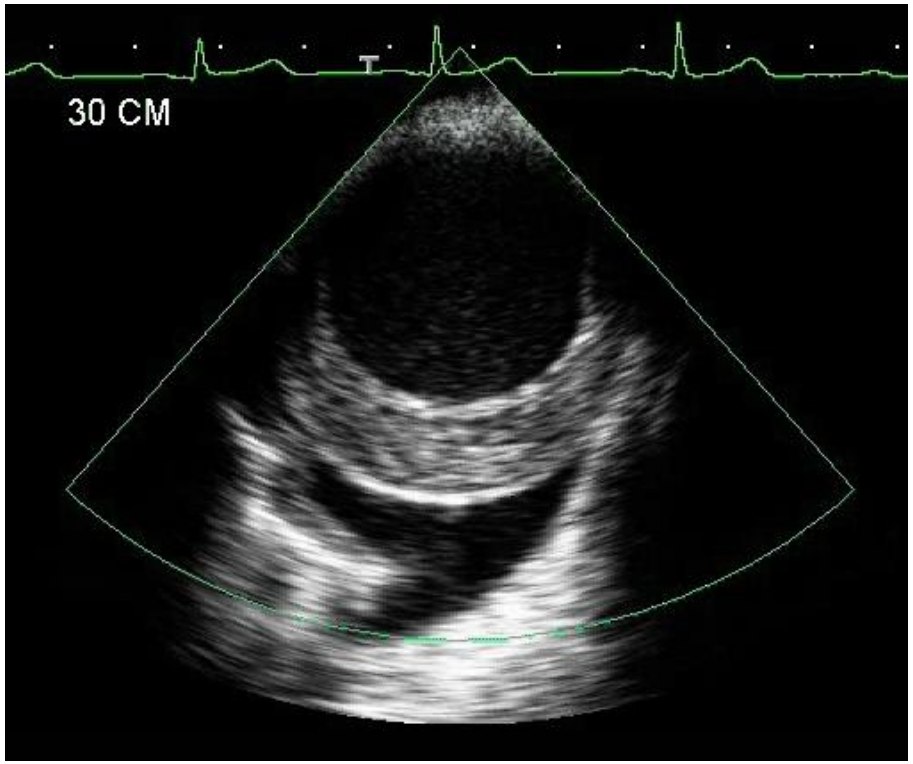

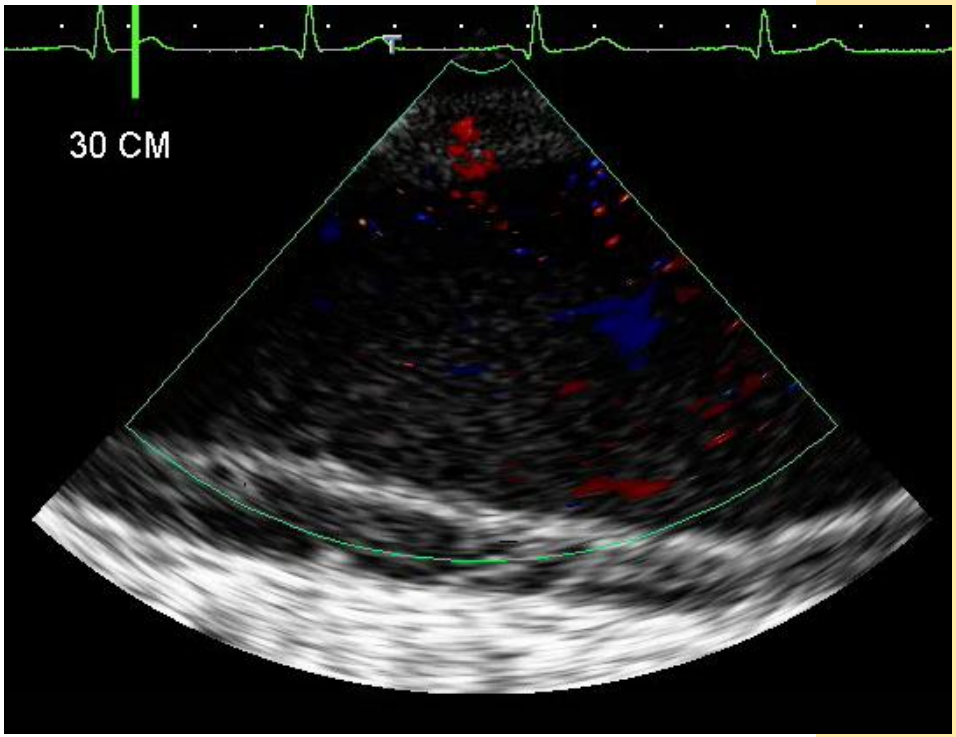

Wichtige Zusatzinfo:
Pleuraerguss !

TEE: Intramurales Hämatom (IMH)

CCB

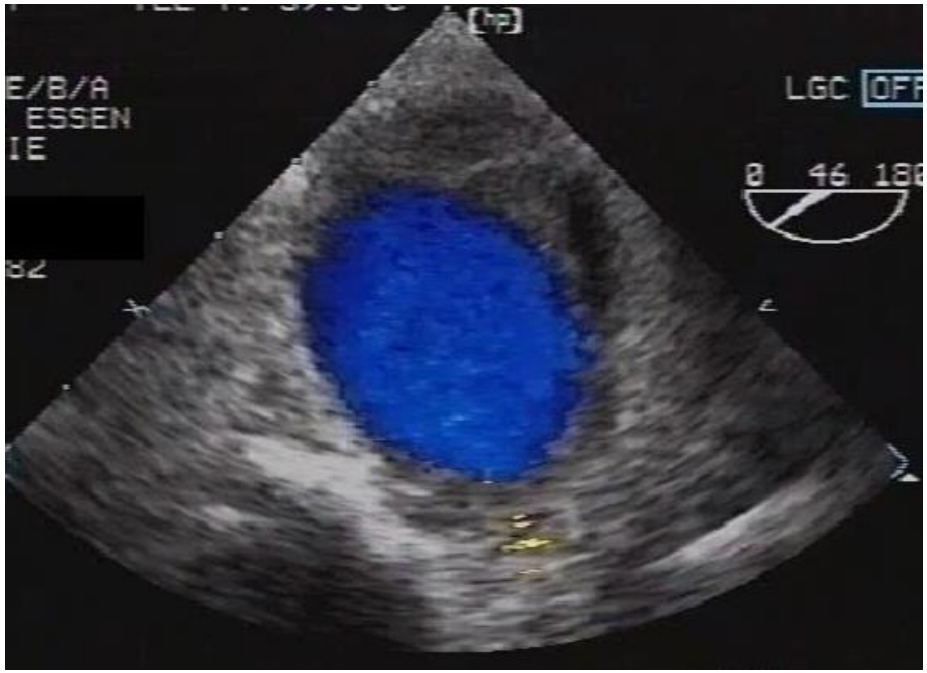

Wichtige Zusatzinfo: Echoarme Zonen = Übergang zur Dissektion

IMH vs. thrombosierte Dissektion vs. Aneurysma

IMH: Intimasklerose
echoarme Zonen

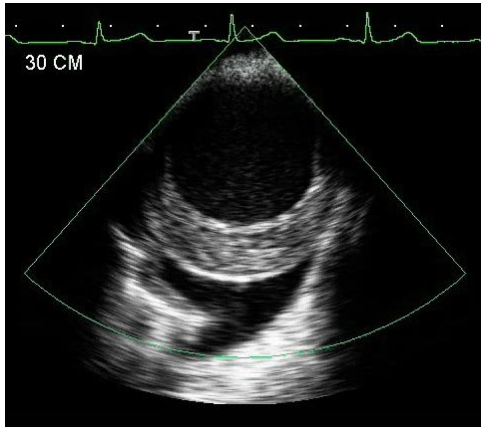

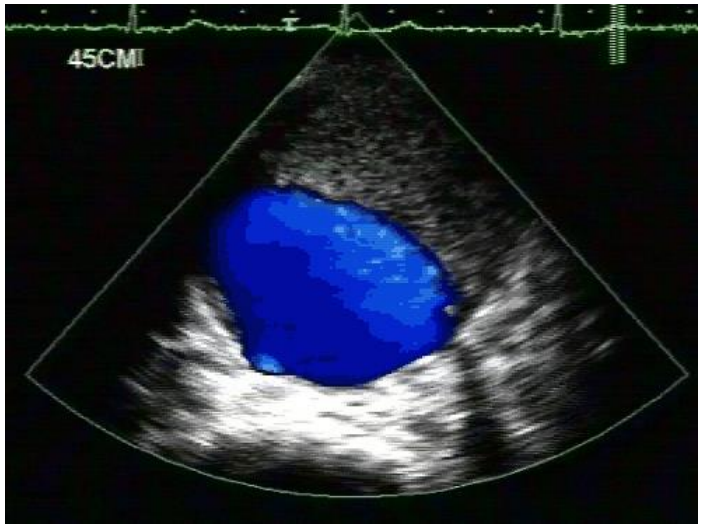

(teil-)thrombosierte Aortendissektion

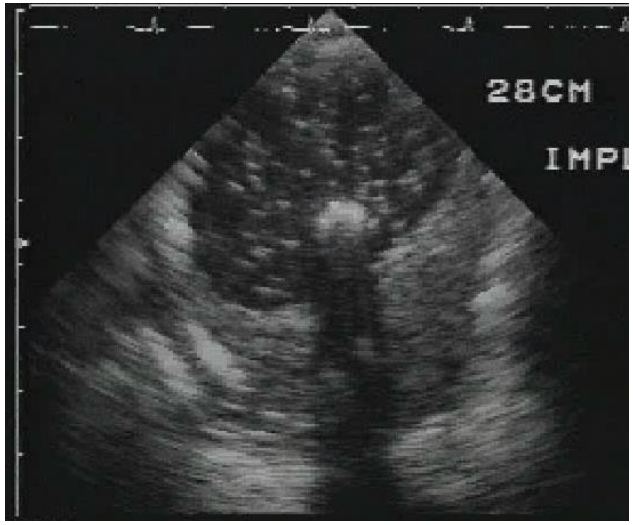

thrombosiertes Aneurysma

TEE: penetrierendes Aortenulcus (PAU)

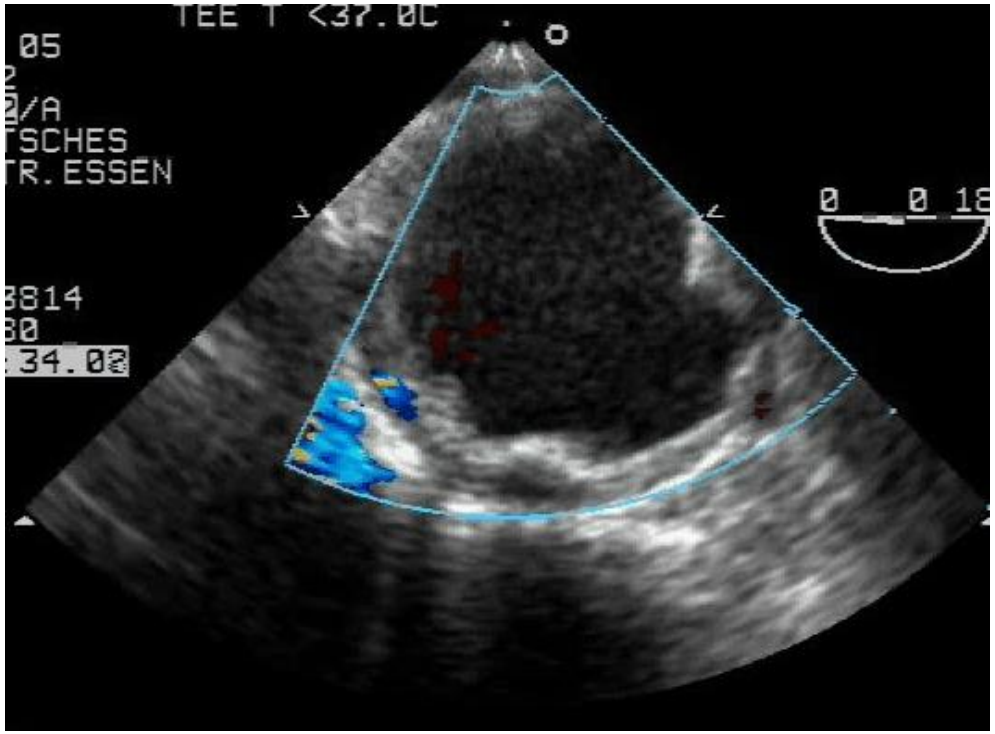

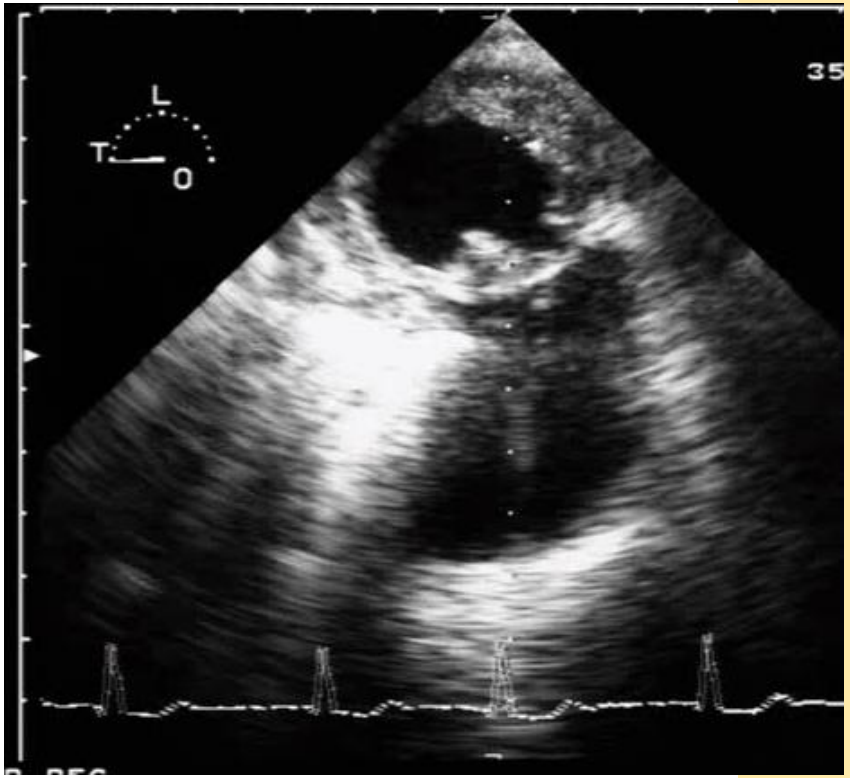

Wichtige Zusatzinfo:
Pleuraerguss !

TEE: penetrierendes Aortenulcus (PAU)

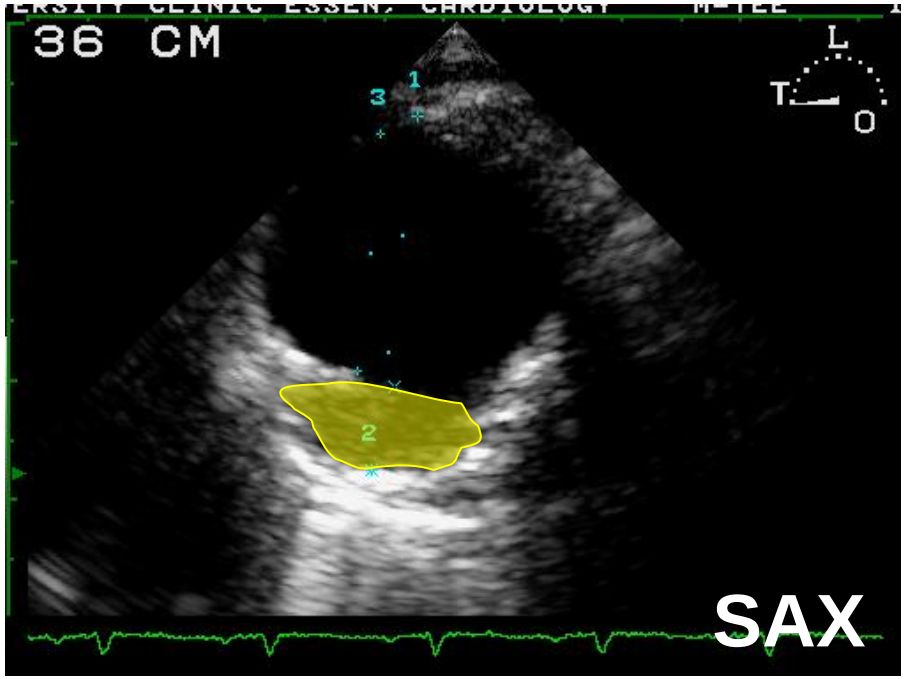

Ausdehnung Tiefe / Breite

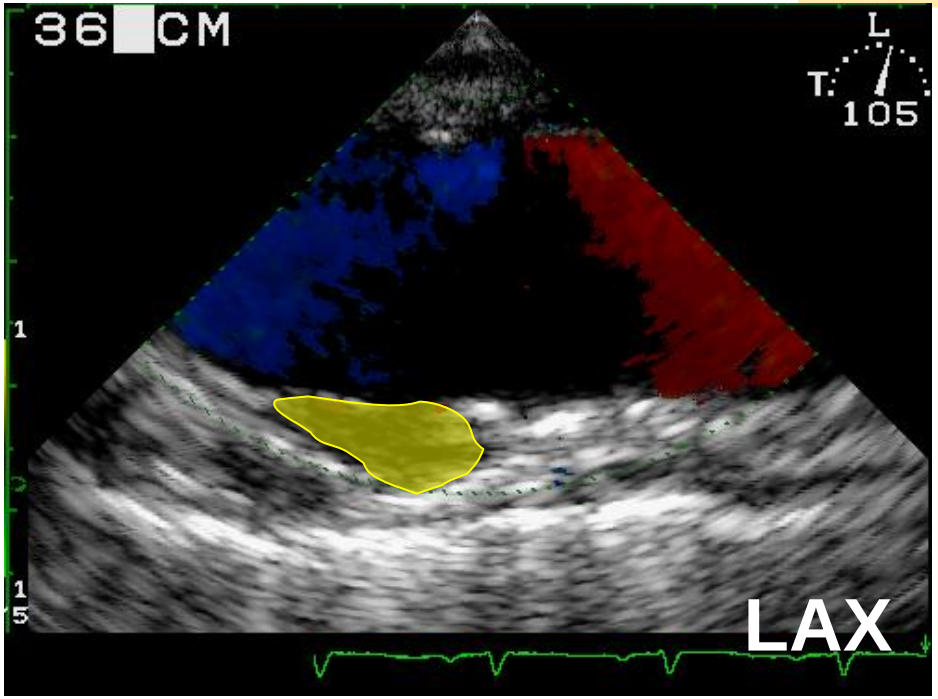

Das sollten Sie mit nach Hause nehmen

CCB

- V.a. akutes Aortensyndrom : rasche Bildgebung, kein Zeitverlust
- CT-A: Bildgebung der 1. Wahl
- Ziele: korrekte Diagnose, Erfassung Komplikationen, kardiale Funktion
- TEE: Komplementäre Zusatz-Informationen
- MRT: Verlaufsuntersuchung bei jungen Patienten

Vielen Dank für Ihre Aufmerksamkeit!